

# Entrapment of a large air bubble at aortic root associated with intra-aortic balloon pump insertion

Hana Kim, Sang-Ik Baek, Hack-Lyoung Kim

## ABSTRACT

**Introduction:** Intra-aortic balloon pump (IABP) and extracorporeal membrane oxygenation (ECMO) are commonly used devices in patients presenting with cardiogenic shock complicated by acute myocardial infarction. The common complications related with these devices are bleeding and thrombosis. On the other hand, air embolism is a very rare complication, especially related to IABP insertion. There has been lack of data on air embolism related to IABP without balloon rupture. **Case Report:** A 59-year-old male with acute myocardial infarction and cardiogenic shock underwent emergent percutaneous coronary intervention (PCI) on ECMO support. After PCI, IABP was inserted via left femoral vein. Immediately after IABP insertion, large air bubble with oscillating motion was found in aortic root. The air bubble was so large that could fill-up almost all part of aortic root. The air bubble was trapped in aortic root and did not move to aortic arch or left ventricle. The air bubble was successfully aspirated using coronary catheter. **Conclusion:** More careful attention should be given during the IABP insertion to prevent air

embolism, especially when there is reverse flow in the aorta by ECMO.

**Keywords:** Acute myocardial infarction, Air embolism, Cardiogenic shock, Extracorporeal membrane oxygenation, Intra-aortic balloon pump

### How to cite this article

Kim H, Sang-Ik B, Hack-Lyoung K. Entrapment of a large air bubble at aortic root associated with intra-aortic balloon pump insertion. Video J Cardiol 2017;1:1–5.

Article ID: 100001VAM02HK2017

\*\*\*\*\*

doi:10.5348/VAM02-2017-1-CR-1

## INTRODUCTION

Intra-aortic balloon pump (IABP) and extracorporeal membrane oxygenation (ECMO) provide circulatory assistance for the failing or ischemic heart, and have been applied in patients with cardiogenic shock complicating acute myocardial infarction (AMI) [1]. IABP increases diastolic blood pressure, decreases left ventricular afterload and increases coronary perfusion [2]. The ECMO provides systemic circulatory support including oxygenation and perfusion [3]. Sometimes IABP and ECMO are simultaneously used because of their synergistic effects and complementary roles [4, 5]. Although there have been contradicting results, IABP improves hemodynamic profiles, and is associated with better clinical outcomes in selected patients [1]. Common complications related to IABP and ECMO are

Hana Kim<sup>1</sup>, Sang-Ik Baek<sup>1</sup>, Hack-Lyoung Kim<sup>1</sup>

**Affiliations:** <sup>1</sup>MD, Department of Internal Medicine, Boramae Medical Center, Seoul National University College of Medicine, Seoul, Korea.

**Corresponding Author:** Hack-Lyoung Kim, MD., PhD, Division of Cardiology, Department of Internal Medicine, Boramae Medical Center, Seoul National University College of Medicine, 20 Boramae-ro 5-gil, Dongjak-gu, Seoul 07061, Korea; E-mail: kh12876@gmail.com

Received: 27 October 2016  
Accepted: 30 January 2017  
Published: 15 February 2017

bleeding, thromboembolism, coagulation abnormality, infection, vessel perforation, and distal ischemia related cannulation [1, 6–8]. Otherwise, air embolism related to IABP or ECMO is rare event. Several air embolism cases have been reported when central catheter was inserted or access line was decannulated during ECMO support [7]. Gas embolization secondary to IABP balloon rupture also has been reported [9]. However, there has been lack of data on air embolism related to IABP without balloon rupture. As an air embolism can be fatal, clinicians should firstly know what situation it can occur, and make an every effort to prevent it when they encounter such situation. Herein, we report a case of large air embolism during IABP insertion in a patient with ECMO support for AMI complicated by cardiogenic shock. The purpose of this case report is to alert interventional cardiologist to the occurrence of air embolism during IABP insertion, especially in patients with ECMO support.

## CASE REPORT

A 59-year-old male visited our emergency room with severe anterior chest pain and loss of consciousness, which suddenly developed 30 minutes ago when he was having dinner. He had received percutaneous coronary intervention (PCI) due to one vessel coronary artery disease in another hospital nine years ago. Recently, he has been free of chest discomfort and had regular check-ups. His initial systolic blood pressure was 62 mmHg and heart rate was 51 per minute. His initial electrocardiogram (ECG) showed markedly elevated ST segment on leads II, III, aVF and complete atrioventricular block (Figure 1A). In a serial follow-up of cardiac enzyme, CK-MB was elevated up to 1,330 ng/ml (normal range: 0–3.6 ng/ml) and troponin I 500 ng/ml (normal range: 0–0.05 ng/ml). Left ventricular function was preserved and there was no regional wall motion abnormality in bed-side echocardiography. There was mild functional mitral regurgitation, and the morphology and function of aortic valve was normal. He was suspected as cardiogenic shock in AMI, and underwent emergency coronary angiography (CAG) on the support of inotropes and vasopressors. In catheterization laboratory, his ECG changed to pulseless ventricular fibrillation (VF) just before CAG (Figure 1B).

In spite of several times of electrical defibrillation, VF persisted. Then, cardiopulmonary resuscitation (CPR) was started, and venoarterial ECMO (VA-ECMO) was applied through right femoral artery and vein. During the CPR on ECMO support, emergent CAG was performed. Coronary angiography showed thrombotic total occlusion of mid-portion of right coronary artery (RCA) (TIMI [thrombolysis in myocardial infarction] flow 0) and stent thrombosis at left main stent prohibiting distal flow to left anterior descending (LAD) and left circumflex artery

(LCX) territories (TIMI flow 2) (Figures 2A–B). Right coronary artery was revascularized using drug-eluting stent (everolimus-eluting stent [Promus Premier™], 4.0×38 mm sized, Boston Scientific, Natick, MA, USA) (Figure 2C), and left main coronary artery and LCX were revascularized by plain balloon angioplasty (Figure 2D). Revascularization was successful, and there was TIMI 2 flow of all three coronary arteries after PCI. In order to reduce left ventricular filling pressure and improve coronary flow, we decided to insert IABP. IABP was inserted via left femoral artery, and placed between the orifice of left subclavian and renal arteries. Immediately after IABP insertion, large air bubble with oscillating motion was found in aortic root (Video 1). The air bubble was so large that could fill-up almost all part of aortic root. The air bubble was trapped in aortic root and did not move to aortic arch or left ventricular. The air bubble was successfully aspirated using 7-F Judkin right coronary catheter. After aspiration, no air bubble was visible in aortic root (Video 2). After PCI, he was admitted to intensive care unit and supported by full medical and mechanical support. However, he was not recovered from cardiogenic shock, and died at the fourth day of admission.

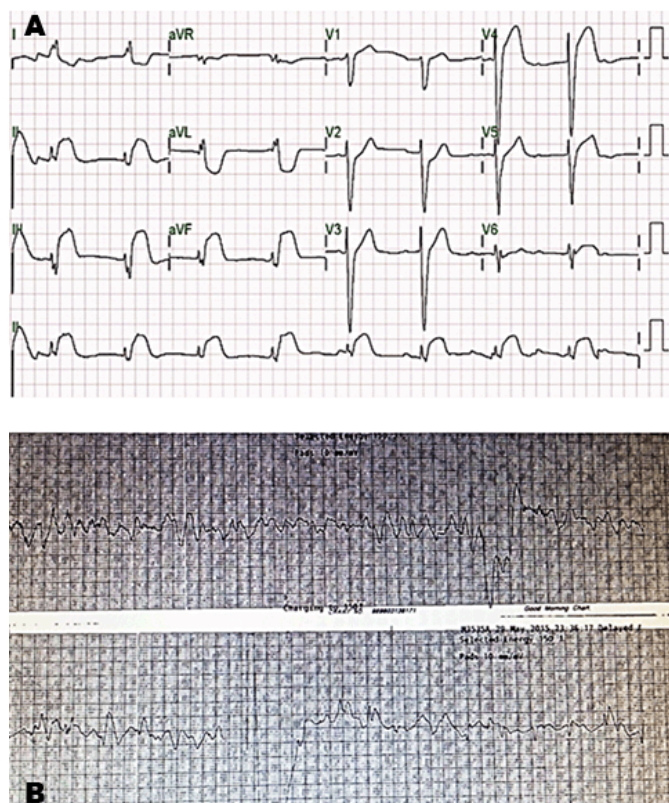


Figure 1: Electrocardiograms (A) Markedly elevated ST segments on multiple leads and complete atrioventricular block at initial admission, and (B) Ventricular fibrillation just before coronary angiography.

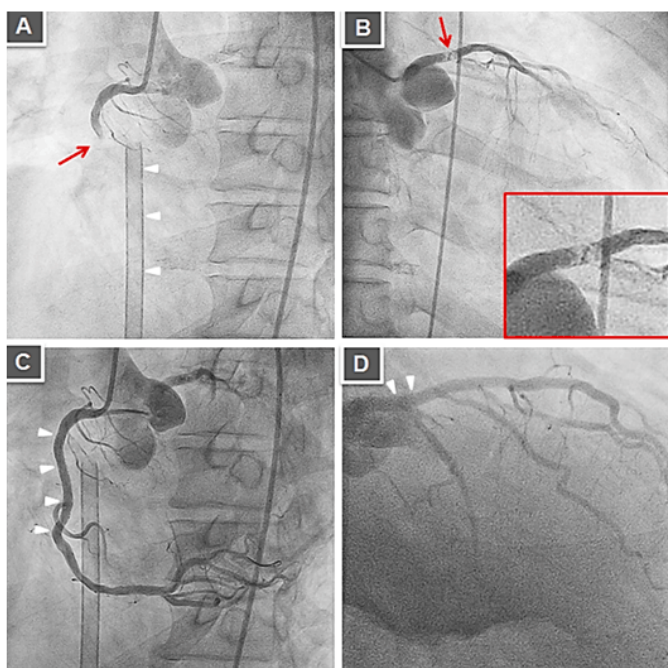


Figure 2: (A) Coronary angiography showing thrombotic total occlusion of mid-portion of right coronary artery (red arrow). Venous catheter of venoatrial extracorporeal membrane oxygenation is seen (white arrow heads), (B) Stent thrombosis is seen at left main prohibiting distal flow to left anterior descending artery and left circumflex artery territories (red arrow and magnification with red box), (C) Successful revascularization was done with drug-eluting stent to right coronary artery (white arrowheads), and (D) With plain balloon to left main (white arrow heads).

## VIDEOS

Video 1: A large air bubble trapped in aortic root with oscillating motion in aortic root.

Video 2: Successful aspiration of air bubble trapped in aortic root using coronary guiding catheter.

**Video url:** [http://videojournalofcardiology.com/archive/early-view-videos/01\\_VAM02\\_2016100001\\_CR\\_EV/01\\_VNP01\\_2016060001\\_CV\\_EV.php](http://videojournalofcardiology.com/archive/early-view-videos/01_VAM02_2016100001_CR_EV/01_VNP01_2016060001_CV_EV.php)

## DISCUSSION

We report a rare case showing a huge air bubble trapped in aortic root immediately after IABP insertion in patients on VA-ECMO support due to cardiogenic shock complicated by AMI. There are many complications associated with IABP and ECMO. However, air embolism related to IABP insertion has not been reported. Although exact mechanism on the formation of large air bubble in the aortic root is unknown, we think that reverse flow by ECMO might be a driving force of external air into the aorta through IABP catheter. Our case emphasizes the importance of cautious IABP insertion especially in a patient receiving VA-ECMO support.

The IABP and the ECMO have been widely used for circulatory support in patients with cardiogenic shock secondary to AMI. The IABP counter-pulsation increases coronary flow and reduces left ventricular afterload, and thus, it improved myocardial perfusion and performance [2]. However, evidence on mortality benefit of IABP in patients with AMI complicated by cardiogenic shock is still limited in the PCI era. In spite of significant mortality reduction by IABP in patients with thrombolytic therapy, recent trials and meta-analyses did not show beneficial effect of IABP in improvement of mortality among patients presenting with AMI complicated by cardiogenic shock and treated with PCI. However, current guidelines recommend the use of IABP in patients with myocardial infarction complicated by cardiogenic shock when the patient is not stabilized with medical therapy, based on the consideration of pathophysiological mechanism and non-randomized trials and registry data [10]. Supporting this, a recent study showed that additional use of IABP showed improved multi-organ dysfunction syndrome, cardiac index, or systemic inflammatory activation in patients with AMI complicated by cardiogenic shock [11]. The ECMO provides more comprehensive cardiopulmonary support than IABP by replacing the pumping function from failing heart and oxygenation from the lungs with congestion [3]. Observational studies showed that the use of ECMO improved survival in patients with cardiogenic shock secondary to AMI [1, 3]. ECMO is also useful in refractory ventricular arrhythmia [1, 3] that was the main cause of the start of ECMO in our case. The concomitant use of ECMO and IABP also has been increased because there is pathophysiological background that vacuum effect of IABP during systole can reduce increased afterload by ECMO [4]. In addition, it has been also suggested that IABP-induced pulsatility significantly improves diastolic filling index and coronary flow by lowering coronary vascular resistance during non-pulsatile peripheral ECMO [5].

Some complications related ECMO and IABP support are known. These are bleeding (33%), hemolysis (18%), leg ischemia (10%), venous thrombosis (10%), central nervous system complications (8%) and so on [8]. Air embolism is hardly occurred during ECMO or IABP insertion. Air within the ECMO circuit makes up approximately 4% of the reported complications [3]. In case of central cannula insertion or manipulation during ECMO support, some air could enter the ECMO circuit. In addition, a small tear within the wall of the membrane oxygenator may lead to a significant air embolus. Least commonly, super saturation of the blood with oxygen may result in the oxygen being forced out of solution [3]. In regard to IABP, Some cases of air embolism due to balloon rupture during IABP support were reported [9]. However, air embolism related IABP insertion is very rare event, and has not been documented. In this case, air embolism occurred when IABP insertion. It is a general concept that air cannot usually entered through IABP catheter due to forward blood flow from heart to

distal body area. The source of a huge air bubble in the aortic root following IABP insertion was still unknown. However, we can suggest a possible mechanism: ECMO made retrograde blood flow from the device to heart, thus room air into the aorta was possible during IABP insertion by sucking power of ECMO. Fortunately, air bubble was not further embolized to the brain or other vital organs, which might cause catastrophic events. The air was entrapped in aortic root by the ECMO flow toward the heart, and successfully removed by catheter. To the best of our knowledge, this is the first report about air embolism related IABP insertion with ECMO support.

## CONCLUSION

With increased number of patients who are diagnosed as cardiogenic shock complicating acute myocardial infarction, the use of intra-aortic balloon pump (IABP) and extracorporeal membrane oxygenation (ECMO) also has been increased. More careful attention should be given during the IABP insertion to prevent air embolism, especially when there is reverse flow in the aorta by ECMO.

\*\*\*\*\*

## Author Contributions

Hana Kim – Acquisition of data, Analysis and interpretation of data, Drafting the article, Revising it critically for important intellectual content, Final approval of the version to be published

Sang-Ik Baek – Acquisition of data, Analysis and interpretation of data, Revising it critically for important intellectual content, Final approval of the version to be published

Hack-Lyoung Kim – Substantial contributions to conception and design, Analysis and interpretation of data, Drafting the article, Revising it critically for important intellectual content, Final approval of the version to be published

## Guarantor

The corresponding author is the guarantor of submission.

## Conflict of Interest

Authors declare no conflict of interest.

## Copyright

© 2017 Hana Kim et al. This article is distributed under the terms of Creative Commons Attribution License which permits unrestricted use, distribution and reproduction in any medium provided the original author(s) and original publisher are properly credited. Please see the copyright policy on the journal website for more information.

## REFERENCES

1. Rihal CS, Naidu SS, Givertz MM, et al. 2015 SCAI/ACC/HFSA/STS clinical expert consensus statement on the use of percutaneous mechanical circulatory support devices in cardiovascular care. *J Am Coll Cardiol* 2015 May 19;65(19):e7–e26.
2. Papaioannou TG, Stefanadis C. Basic principles of the intraaortic balloon pump and mechanisms affecting its performance. *ASAIO J* 2005 May–Jun;51(3):296–300.
3. Allen S, Holena D, McCunn M, Kohl B, Sarani B. A review of the fundamental principles and evidence base in the use of extracorporeal membrane oxygenation (ECMO) in critically ill adult patients. *J Intensive Care Med* 2011 Jan–Feb;26(1):13–26.
4. Koeckert MS, Jorde UP, Naka Y, Moses JW, Takayama H. Impella LP 2.5 for left ventricular unloading during venoarterial extracorporeal membrane oxygenation support. *J Card Surg* 2011 Nov;26(6):666–8.
5. Madershahian N, Wippermann J, Liakopoulos O, et al. The acute effect of IABP-induced pulsatility on coronary vascular resistance and graft flow in critical ill patients during ECMO. *J Cardiovasc Surg (Torino)* 2011 Jun;52(3):411–8.
6. Bahekar A, Singh M, Singh S, et al. Cardiovascular outcomes using intra-aortic balloon pump in high-risk acute myocardial infarction with or without cardiogenic shock: A meta-analysis. *J Cardiovasc Pharmacol Ther* 2012 Mar;17(1):44–56.
7. Faulkner SC, Chipman CW, Baker LL. Troubleshooting the extracorporeal membrane oxygenator circuit and patient. *J Extra Corpor Technol* 1993;24(4):120–9.
8. Zangrillo A, Landoni G, Biondi-Zoccai G, et al. A meta-analysis of complications and mortality of extracorporeal membrane oxygenation. *Crit Care Resusc* 2013 Sep;15(3):172–8.
9. Cruz-Flores S, Diamond AL, Leira EC. Cerebral air embolism secondary to intra-aortic balloon pump rupture. *Neurocrit Care* 2005;2(1):49–50.
10. Anderson JL, Adams CD, Antman EM, et al. 2011 ACCF/AHA Focused update incorporated into the ACC/AHA 2007 guidelines for the management of patients with unstable angina/non-ST-elevation myocardial infarction: A report of the American college of cardiology foundation/American heart association task force on practice guidelines. *Circulation* 2011 May 10;123(18):e426–579.
11. Prondzinsky R, Lemm H, Swyter M, et al. Intra-aortic balloon counterpulsation in patients with acute myocardial infarction complicated by cardiogenic shock: The prospective, randomized IABP Shock Trial for attenuation of multiorgan dysfunction syndrome. *Crit Care Med*. 2010 Jan;38(1):152–60.

Access full text article on  
other devices



Access PDF of article on  
other devices

